

## **CME** Ultrasound-Guided Regional Anesthesia: Current Concepts and Future Trends

Peter Marhofer, MD\*

Vincent W. S. Chan, MD, FRCPC†

The scope of ultrasound imaging guidance for regional anesthesia is growing rapidly. Preliminary data, although limited, suggest that ultrasound can improve block success rate and decrease complications. In this review, we describe the basic principles of ultrasound scanning and needling techniques for nerve blocks, highlight some of the data on clinical outcome, discuss specific limitations of ultrasound for regional anesthesia, and speculate on the future direction for physician training and competency assessment with this technology.

(Anesth Analg 2007;104:1265-9)

**U**ltrasound technology is advancing at a rapid pace. The practice of ultrasound-guided nerve blocks may not require that all practitioners have an in-depth understanding of the physics and technical details behind today's sophisticated ultrasound equipment, just as most of us provide general anesthesia daily without fully understanding the technological details of the anesthetic machine. However, anesthesiologists must understand some basic ultrasound principles that are relevant to clinical practice. This article aims to highlight some aspects of equipment selection and imaging technique, discuss outcome data currently available, and speculate on future trends in ultrasound teaching and training.

### **ULTRASOUND EQUIPMENT AND IMAGING TECHNIQUE**

An ultrasound beam is generated when an electrical field is created across the piezoelectric crystals positioned along the surface of the ultrasound transducer. The beam penetrates body tissue and is reflected, refracted, and scattered after it encounters structures of different acoustic impedance. The ultrasound transducer functions both as a transmitter and a receiver. A clear target image is displayed only when

a strong signal is returned to the transducer. For this reason, image quality and structural echogenicity are highly dependent on the angle of incidence, which is best at 90° (i.e., beam perpendicular to the target). Even with the most sophisticated equipment, a hyperechoic target may appear hypoechoic (a phenomenon called "anisotropy") and may even become invisible when the returning signal is poor (Fig. 1). Ultrasound scanning is therefore a highly technical skill that must be mastered through repetitive hands-on practice.

Many types of ultrasound machines and transducers are now available. Transducers with identical frequency range may not necessarily yield images of similar quality. Image resolution is determined by both the transducer (e.g., number of crystals and control of receive frequency) and the machine (e.g., image processing). (A discussion of the engineering factors governing ultrasound performance is beyond the scope of this review.) While cart-based machines are generally more costly and sophisticated, the latest models of compact portable machines offer image quality and resolution that is adequate for regional anesthesia. Included are basic image optimization features (e.g., time gain compensation and dynamic range), color Doppler capability (to differentiate vascular from nonvascular structures), and image storage features (still images and videos for review).

A safe and successful ultrasound-guided nerve block requires 1) appropriate imaging and detection of target nerve structures, 2) proficiency in tracking needle advancement in real time, and 3) assessment of local anesthetic spread around the target nerve. Ultrasound imaging for upper limb blocks is rather straightforward (1). Ultrasound for lower limb blocks is more challenging (2), whereas neuraxial blockade is most difficult (3). The brachial plexus and peripheral

From the \*Department of Anaesthesia and Intensive Care Medicine, Medical University Vienna, Vienna, Austria; and †Department of Anesthesia, University of Toronto, Toronto, Canada.

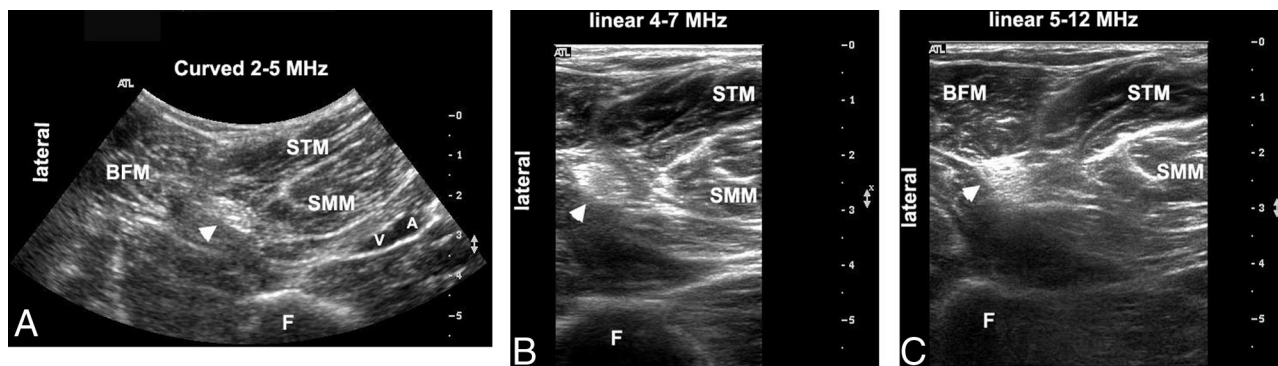
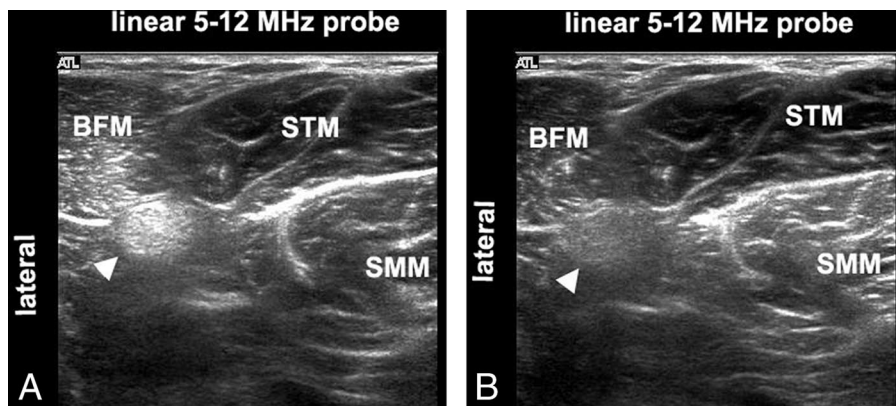
Accepted for publication January 23, 2007.

Address correspondence to Peter Marhofer, MD, Department of Anaesthesia and Intensive Care Medicine, Medical University Vienna, Waehringer Guertel 18-20, A-1090 Vienna, Austria. Address e-mail to peter.marhofer@meduniwien.ac.at.

Reprints will not be available from the author.

Copyright © 2007 International Anesthesia Research Society  
DOI: 10.1213/01.ane.0000260614.32794.7b

**Figure 1.** Demonstration of the effect of anisotropy with the ultrasound probe in the popliteal region. Transverse sonogram captured with the probe at 90° to the sciatic nerve (arrowhead) which appears predominantly hyperechoic (A), and with the probe at 60° resulting in poor visualization (B). BFM = biceps femoris muscle; SMM = semimembranosus muscle; STM = semitendinosus muscle.



**Figure 2.** Variations of popliteal sciatic nerve images. Transverse sonogram captured with a curved 2–5 MHz probe providing a wider field of view (A), with a linear 4–7 MHz probe (B), and a linear 5–12 MHz probe (C) providing a nerve image of higher resolution. A = popliteal artery; Arrowhead = sciatic nerve; BFM = biceps femoris muscle; F = femoral bone; SMM = semimembranosus muscle; STM = semitendinosus muscle; V = popliteal vein.

nerves in the upper limb are superficial structures (within 3–4 cm) even in individuals with a high body mass index. A linear 38-mm high-frequency probe (10–15 MHz) is usually adequate for nerve imaging at the interscalene, axillary, and midhumeral regions and below in the upper extremity. A high-frequency probe with a smaller footprint (hockey stick 25 mm) may be considered in the supraclavicular region when space is limited. On the other hand, a lower frequency probe (7 MHz or less) may be required in the infraclavicular region to image cords of the brachial plexus that are deep (5 cm or more) to the robust pectoralis muscles. Differences in image quality when probes of different frequencies are used in the popliteal region are illustrated in Figure 2.

Lower limb imaging can be especially challenging in the gluteal and subgluteal regions where the sciatic nerve is thin, wide, and deep. In this case, a curved lower frequency probe in the range of 5–7 MHz is indicated to obtain a larger field of view to survey the anatomical structures surrounding the sciatic nerve. For example, identification of the gluteus maximus muscle, ischial bone, ischial spine, and the inferior gluteal artery will help to locate the sciatic nerve in the gluteal region (2). Generally speaking, visualization of the sciatic nerve in the popliteal fossa and the femoral nerve at the inguinal crease is relatively simple.

Neuraxial imaging is technically difficult because bone has high acoustic impedance; that is, the ultrasound beam does not penetrate bone to any great extent (4). The epidural space, dura, and the spinal cord deep to the spine are often overshadowed by the dark hypoechoic bony shadow. Although limited, beam penetration is possible through the interlaminar space or the paramedian window in the adult lumbar space, but is almost inaccessible in the thoracic level (5). Therefore, neuraxial images in adults are often of low resolution and more difficult to interpret. The spines of neonates and infants, on the other hand, are not fully ossified, thus permitting imaging of epidural vascular pulsation, epidural local anesthetic spread, and possibly, the epidural catheter (6–8).

The “ART” of scanning involves three basic transducer movements. Alignment (A) refers to the sliding movement of the transducer along the skin surface to trace the course of a nerve lengthwise. Rotation (R) refers to the clockwise and counterclockwise transducer movement that is most useful for imaging the long axis of a nerve or the block needle by aligning the target with the beam. Tilting (T) refers to the angling movement of the transducer on the skin surface that is useful for optimizing the angle of incidence (90°) and maximizing beam signal return to the transducer in most instances.

There are two scanning approaches to track needle movement in real time and visualize needle advancement (9). The in-plane approach is performed by passing the block needle beneath the long axis of the beam, thus allowing full visualization of the needle shaft and tip. The out-of-plane approach is performed by passing the block needle beneath the short axis of the beam; thus, the needle appears as a bright "dot" in short axis. The in-plane approach is more difficult to perform because it requires precise alignment of the ultrasound beam with the needle and the nerve. For the out-of-plane approach, accurate needle tip localization can be difficult in the absence of a special echogenic design. In this case, the needle tip position is often inferred by observing local tissue movement and a dorsal ultrasound shadow at the time of needle advancement or tissue expansion at the time of fluid injection.

Ultrasound imaging for regional anesthesia has a number of limitations. Image resolution and quality vary inversely with depth of penetration. Thus it is technically challenging to visualize the lumbar plexus within the psoas muscle or the sciatic nerve in the gluteal region. Furthermore, tracking needle movement during the in-plane approach is difficult when the needle and beam are at 45° to each other and the returning signal is weak. Anatomical structures deep to bones, (e.g., neuraxial structures and intercostal nerves) are often shadowed by bone, and imaging accessibility may be highly restricted. It is also challenging to image smaller nerves (<1 cm) in deep locations, (e.g., the lateral femoral cutaneous nerve), but visualization of small superficial nerves [e.g., occipital (10) and ilioinguinal and iliohypogastric nerves (11)] is possible. Lastly, acoustic artifacts seen posterior to vessels (e.g., axillary artery in the infraclavicular region) may be erroneously interpreted as nerves.

## OUTCOME DATA

To some, ultrasonography is the preferred method of nerve localization because of direct visualization of nerves and adjacent anatomical structures. Plausible outcome measures for ultrasound-guided techniques include time of block performance, onset, intensity and duration of sensory and motor block, block-related complications, cost, and patient satisfaction. It is important to note that all outcome studies are small-scaled with limited patient populations; thus, the level of evidence is rather low. Future, large, multicentered trials are necessary to confirm preliminary favorable results. Until confirmation is available, the question of the positive impact on clinical outcome remains largely within the realm of the opinions of "experts" performing ultrasound-guided nerve blocks.

Some case series have demonstrated shortened procedure time and faster block onset compared with conventional techniques. Chan et al. (12) reported

mean onset time of 5 min for supraclavicular blocks with a mixture of lidocaine 2% and bupivacaine 0.5% and a high rate of patient satisfaction. Marhofer et al. (13) observed an onset time of 9 min for infraclavicular blocks in children with ropivacaine 0.5%. In a randomized clinical trial, Williams et al. (14) demonstrated that supraclavicular blocks with ultrasonographic guidance were accomplished faster than with nerve stimulation (5 vs 10 min). Schwemmer et al. (15) reported that surgical procedures could proceed 15 min earlier when axillary blocks were performed under ultrasonographic guidance compared with nerve stimulation. Soeding et al. (16) also reported significantly faster onset time for interscalene and axillary brachial plexus blocks under ultrasound than with conventional anatomical landmark-based methods. Marhofer et al. (17) observed onset times of approximately 13 min for three-in-one blocks with bupivacaine 0.5%, which are approximately 50% faster compared with conventional methods. Longer duration of anesthesia and analgesia has also been reported (13). Significantly, only a few studies have demonstrated overall improved block success rate with the ultrasound technique (11,13,17,18) and not others (14–16).

The high cost of equipment is often the argument against ultrasound-guided techniques. A preliminary study by Sandhu et al. (19) suggests that the cost of using ultrasound and nerve stimulator techniques is similar based on the assumption that the average cost per ultrasound-guided block is \$3.40 (machine, gel and noninsulated Tuohy needle) and the portable machine (SonoSite 180 model) is used for 5000 procedures. Cost analysis for other compact and cart-based machines is not available. Conceivably, price reduction with time and achievement of consistent block may justify routine use of ultrasound in the future.

Patient satisfaction is another important measure of clinical outcome. To the patient, a nerve block deemed perfect by the anesthesia provider may be viewed as disappointing by the patient if severe pain is experienced during block performance, particularly when the pain is aggravated in a fractured limb by muscle contraction during nerve stimulation. Ultrasound-guided nerve blocks can be a relatively painless procedure when muscle contraction is avoided without nerve stimulation (13,16).

One potentially significant impact of the ultrasound-guided technique is reduction in block-related complications. Reports of complications associated with peripheral nerve blocks often appear as case reports (20–22). Conceivably, many others go unreported. Visualization of needle to nerve contact and their interaction may help reduce nerve injury, although this is a matter of speculation. Given the low incidence of complication [0.002% in Auroy et al.'s (23) study], it is difficult, if not impossible, to evaluate nerve injury associated with ultrasound-guided nerve blocks because an extraordinarily large study patient population is required. In an

animal study, Chan (24) observed an expansion in nerve diameter after 1–2 mL of dye injected intraneurally. Whether an ultrasound warning signal can prevent further injection within the nerve and reduce nerve injury in the clinical setting remains to be determined. Bigeleisen (25) observed ultrasound evidence of intraneural injection (nerve swelling) during axillary block using a 22-G B-bevel needle. Fortunately, intraneural injury did not occur after 2–3 mL of local anesthetic injection. Schafhalter-Zoppoth et al. (26) also observed ultrasound evidence of an intraneural injection-nerve compression as opposed to expansion during a femoral nerve block. Future studies are required to more specifically define the ultrasonographic and morphologic signs of an intraneural injection and assess the clinical utility of ultrasound for detection of intraneural needle placement.

Another potential benefit of ultrasound-guided peripheral nerve block is a reduction in the incidence of systemic local anesthetic toxicity. The minimum effective dose of local anesthetic can be significantly reduced with the ultrasound technique (11,17,27). Furthermore, ultrasound can differentiate an intravascular from an extravascular injection based on the pattern of local anesthetic spread. Other advantages include direct visualization of non-neural structures, e.g., pleura and kidney, thus preventing accidental puncture during periclavicular blocks and psoas compartment block.

Some may argue that one other common complication not often mentioned is *failed block*. In daily clinical practice, a failed peripheral nerve block could be considered a major complication and is associated with patient discomfort and unnecessary conversion to general anesthesia. Depending on the applied definition of block success, different failure rates are reported, but a reliable percentage is described in a survey from Grau et al. (28) in which an average of approximately 20% failure rate for peripheral nerve blocks is described. The reported success rate of ultrasound-guided block ranges from 55% to 100% (13,14).

## FUTURE TRENDS

Ultrasound technology will continue to evolve, providing further improvements in portability, ubiquity, image processing, and display. Similar to the computer and telephone industry, ultrasound equipment will likely become smaller, highly mobile, potentially cordless, and available for use at the point of care anywhere at anytime. Enhanced imaging capability of compact machines may one day rival those of the large cart-based machines, and lower prices and user-friendly simplicity will improve accessibility.

If ultrasound is to become an integral part of regional anesthesia, future guidelines and teaching curricula must be established for proper training. In a recent editorial, Bodenham (29) questioned the need for skill assessment and accreditation for individual

anesthesiologists prior to clinical use of ultrasound imaging. Guidelines are needed to define training, competency, and scope of practice similar to those established for ultrasound imaging by emergency physicians (30). Recently published guidelines for regional anesthesia fellowship training classify nerve block procedures into different levels of technical complexity: basic, intermediate, and advanced (31). A similar classification may be adopted for ultrasound-guided techniques.

At the present time, teaching resources for ultrasound-guided nerve blocks are limited but atlases, textbooks, and web-based learning materials are forthcoming. Furthermore, the best way to teach has yet to be determined. Ideally, a structured residency teaching curriculum will teach both the cognitive and manual component of the ultrasound-guided technique. Important topics to be covered include equipment selection and functionality, basic ultrasound physics, imaging principles relevant to clinical practice, hands-on scanning skills, sonoanatomy, needling approaches, image interpretation of local anesthetic spread, ultrasound artifacts, and safety issues. Among these topics, visually tracking needle advancement (in-plane and out-of-plane approaches) may be most challenging, but such skills can be learned through practice on an agar or meat (32) phantom. Preliminary data from Sites et al. (33) showed that junior residents could rapidly acquire ultrasound technical skills. Cumulative sum (cusum) analysis has been used to objectively assess resident proficiency in technical anesthesiology procedures (34). Objective structured assessment of technical skills has also been shown to reliably assess surgical skills using global ratings and task-specific checklists (35). Conceivably, both cusum analysis and objective structured assessment of technical skills can be used for assessing ultrasound technical skills.

In summary, ultrasound-guided regional anesthesia is an evolving and exciting field that invites clinician participation and learning. Future educational guidelines and prospective outcome studies are needed to establish training requirements and further define the clinical benefits.

## ACKNOWLEDGMENTS

*Vincent Chan received ultrasound equipment support for research from SonoSite, GE Healthcare, and Philips Medical System.*

## REFERENCES

1. Marhofer P, Greher M, Kapral S. Ultrasound guidance in regional anaesthesia. *Br J Anaesth* 2005;94:7–17.
2. Chan VW, Nova H, Abbas S, et al. Ultrasound examination and localization of the sciatic nerve: a volunteer study. *Anesthesiology* 2006;104:309–14.
3. Grau T. Ultrasonography in the current practice of regional anaesthesia. *Best Pract Res Clin Anaesthesiol* 2005;19:175–200.
4. Grau T, Leopold RW, Conradi R, et al. Efficacy of ultrasound imaging in obstetric epidural anesthesia. *J Clin Anesth* 2002; 14:169–75.

5. Grau T, Leipold RW, Delorme S, et al. Ultrasound imaging of the thoracic epidural space. *Reg Anesth Pain Med* 2002;27:200–6.
6. Willschke H, Marhofer P, Bosenberg A, et al. Epidural catheter placement in children: comparing a novel approach using ultrasound guidance and a standard loss-of-resistance technique. *Br J Anaesth* 2006;97:200–7.
7. Rapp HJ, Folger A, Grau T. Ultrasound-guided epidural catheter insertion in children. *Anesth Analg* 2005;101:333–9.
8. Marhofer P, Bosenberg A, Sitzwohl C, et al. Pilot study of neuraxial imaging by ultrasound in infants and children. *Paediatr Anaesth* 2005;15:671–6.
9. Gray AT. Ultrasound-guided regional anesthesia: current state of the art. *Anesthesiology* 2006;104:368–73.
10. Eichenberger U, Greher M, Kapral S, et al. Sonographic visualization and ultrasound-guided block of the third occipital nerve: prospective for a new method to diagnose C2–C3 zygapophysial joint pain. *Anesthesiology* 2006;104:303–8.
11. Willschke H, Marhofer P, Bosenberg A, et al. Ultrasonography for ilioinguinal/iliohypogastric nerve blocks in children. *Br J Anaesth* 2005;95:226–30.
12. Chan VW, Perlas A, Rawson R, Odukoya O. Ultrasound-guided supraclavicular brachial plexus block. *Anesth Analg* 2003;97:1514–17.
13. Marhofer P, Sitzwohl C, Greher M, Kapral S. Ultrasound guidance for infraclavicular brachial plexus anaesthesia in children. *Anaesthesia* 2004;59:642–6.
14. Williams SR, Chouinard P, Arcand G, et al. Ultrasound guidance speeds execution and improves the quality of supraclavicular block. *Anesth Analg* 2003;97:1518–23.
15. Schwemmer U, Markus CK, Greim CA, et al. Ultrasound-guided anaesthesia of the axillary brachial plexus: efficacy of multiple injection approach. *Ultraschall Med* 2005;26:114–19.
16. Soeding PE, Sha S, Royse CE, et al. A randomized trial of ultrasound-guided brachial plexus anaesthesia in upper limb surgery. *Anaesth Intensive Care* 2005;33:719–25.
17. Marhofer P, Schrogendorfer K, Wallner T, et al. Ultrasonographic guidance reduces the amount of local anesthetic for 3-in-1 blocks. *Reg Anesth Pain Med* 1998;23:584–8.
18. Sites BD, Beach ML, Spence BC, et al. Ultrasound guidance improves the success rate of a perivascular axillary plexus block. *Acta Anaesthesiol Scand* 2006;50:678–84.
19. Sandhu NS, Sidhu DS, Capan LM. The cost comparison of infraclavicular brachial plexus block by nerve stimulator and ultrasound guidance. *Anesth Analg* 2004;98:267–8.
20. Ben David B, Stahl S. Axillary block complicated by hematoma and radial nerve injury. *Reg Anesth Pain Med* 1999;24:264–6.
21. Weller RS, Gerancher JC, Crews JC, Wade KL. Extensive retroperitoneal hematoma without neurologic deficit in two patients who underwent lumbar plexus block and were later anticoagulated. *Anesthesiology* 2003;98:581–5.
22. Nielsen CH. Bleeding after intercostal nerve block in a patient anticoagulated with heparin. *Anesthesiology* 1989;71:162–4.
23. Auroy Y, Benhamou D, Bargues L, et al. Major complications of regional anesthesia in France: the SOS Regional Anesthesia Hotline Service. *Anesthesiology* 2002;97:1274–80.
24. Chan VW. Ultrasound evidence of intraneural injection. *Anesth Analg* 2005;101:610–11.
25. Bigeleisen PE. Nerve puncture and apparent intraneural injection during ultrasound-guided axillary block does not invariably result in neurologic injury. *Anesthesiology* 2006;105:779–83.
26. Schafhalter-Zoppoth I, Zeitz ID, Gray AT. Inadvertent femoral nerve impalement and intraneural injection visualized by ultrasound. *Anesth Analg* 2004;99:627–8.
27. Sandhu NS, Maharlouei B, Patel B, et al. Simultaneous bilateral infraclavicular brachial plexus blocks with low-dose lidocaine using ultrasound guidance. *Anesthesiology* 2006;104:199–201.
28. Grau T, Fatehi S, Motsch J, Bartussek E. [Survey on current practice of regional anaesthesia in Germany, Austria, and Switzerland, Part 2: Use, success rates and techniques]. *Anaesthesist* 2004;53:847–55.
29. Bodenham AR. Editorial II. Ultrasound imaging by anaesthetists: training and accreditation issues. *Br J Anaesth* 2006;96:414–17.
30. American College of Emergency Physicians. ACEP emergency ultrasound guidelines—2001. *Ann Emerg Med* 2001;38:470–81.
31. Hargett MJ, Beckman JD, Liguori GA, Neal JM. Guidelines for regional anesthesia fellowship training. *Reg Anesth Pain Med* 2005;30:218–25.
32. Xu D, Abbas S, Chan VW. Ultrasound phantom for hands-on practice. *Reg Anesth Pain Med* 2005;30:593–4.
33. Sites BD, Gallagher JD, Cravero J, et al. The learning curve associated with a simulated ultrasound-guided interventional task by inexperienced anesthesia residents. *Reg Anesth Pain Med* 2004;29:544–8.
34. Naik VN, Matsumoto ED, Houston PL, et al. Fiberoptic orotracheal intubation on anesthetized patients: do manipulation skills learned on a simple model transfer into the operating room. *Anesthesiology* 2001;95:343–8.
35. Martin JA, Regehr G, Reznick R, et al. Objective structured assessment of technical skill (OSATS) for surgical residents. *Br J Surg* 1997;84:273–8.